

## Case Report

Fatal *Ophiostoma piceae* infection in a patient with acute lymphoblastic leukaemia

Martin Bommer,<sup>1</sup> Marie-Luise Hütter,<sup>1</sup> Stephan Stilgenbauer,<sup>1</sup>  
G. Sybren de Hoog,<sup>2</sup> Z. Wilhelm de Beer<sup>3</sup> and Nele Wellinghausen<sup>4</sup>

## Correspondence

Nele Wellinghausen  
nele.wellinghausen@web.de

<sup>1</sup>Department of Internal Medicine III, University Hospital of Ulm, Germany

<sup>2</sup>Centraalbureau voor Schimmelcultures (CBS), Utrecht, The Netherlands

<sup>3</sup>Department of Microbiology and Plant Pathology, Forestry and Agricultural Biotechnology Institute (FABI), University of Pretoria, South Africa

<sup>4</sup>Institute of Medical Microbiology and Hygiene, University Hospital of Ulm, Germany

Received 23 July 2008  
Accepted 17 November 2008

We report to our knowledge the first case of human infection with *Ophiostoma piceae*. This *Sporothrix schenckii*-related fungus caused disseminated infection involving the lung and the brain in a patient with lymphoblastic lymphoma. The case emphasizes the significance of molecular techniques for identification of rare fungi in the clinical microbiology laboratory.

## Case report

A 41-year-old gardener was admitted to the University Hospital of Ulm due to renal failure. Kidney biopsy revealed diffuse involvement of both kidneys by lymphoblastic lymphoma. Additional but asymptomatic cerebral involvement was suspected on magnetic resonance imaging (MRI) (multiple small spots with contrast enhancement). Bone marrow biopsy showed only minimal infiltration. In his past medical history, only testicular cancer 10 years ago was remarkable, which was successfully treated by semi-castration and chemotherapy. After confirmation of lymphoblastic lymphoma, chemotherapy was initiated according to the German Acute Lymphoblastic Leukemia study group (GMALL 07/03) with dexamethasone, vincristine, daunorubicin, cyclophosphamide and PEG-asparaginase [study protocol available in short form from the website of the European LeukemiaNet (Hoelzer, 2006)]. The prophylactic antimicrobial regimen consisted of levofloxacin (500 mg per day per os) and amphotericin B (30 ml per day per os), which was replaced by fluconazole (100 mg daily per os) and subsequently by voriconazole (400 mg per day per os) during induction therapy I. Twenty-eight days after start of induction therapy II (designated day 0), the patient was readmitted to the University Hospital of Ulm complaining of fever of up to 40 °C, dyspnoea and chest pain. Two non-ulcerated skin

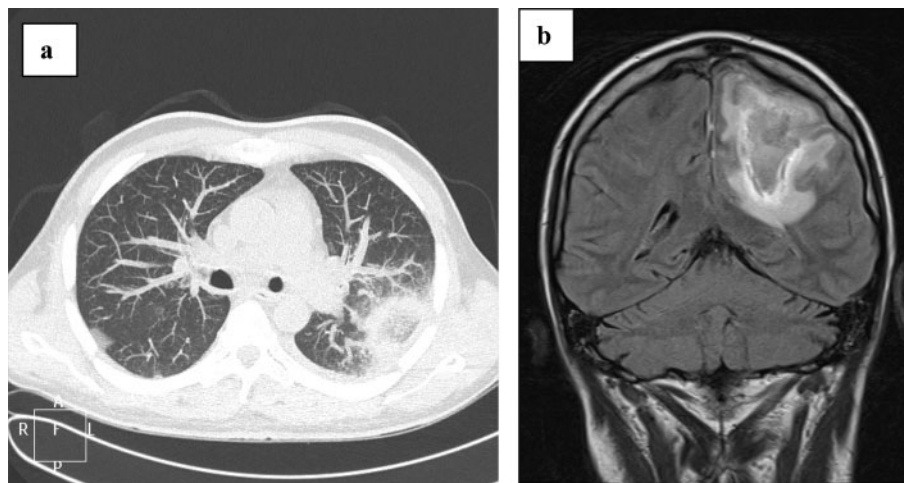
lesions with a diameter of 2 × 2 cm showing a reddened margin were detected at the former insertion sites of a central vascular catheter in the jugular region and of a bone marrow biopsy at the hip. On the day of admission, the patient had severe neutropenia (granulocytes  $0.1 \times 10^9 \text{ l}^{-1}$ ) and the C-reactive protein level was  $306 \text{ mg l}^{-1}$ . Empirical antimicrobial therapy was started immediately with piperacillin/tazobactam (4.5 g three times daily) and clindamycin (600 mg three times daily). Computed tomography (CT) of the chest on day 2 revealed left-sided infiltrates suspicious of fungal infection (Fig. 1a). Thus anti-infective therapy was changed from voriconazole (which had been given for a total of 43 days) to posaconazole (800 mg per day), imipenem (500 mg four times a day) and linezolid (600 mg twice daily). Bronchoscopy was performed on day 3, but bronchial fluid was negative for fungi, pathogenic bacteria and mycobacteria. Three sets of blood cultures remained sterile. On day 3, right-sided hemiparesis developed. MRI of the head was performed on day 5 and revealed a cerebral lesion of 60 × 39 mm in size suspicious of fungal infection (Fig. 1b). Due to stimulation with granulocyte growth factor (480 µg daily), leukocyte counts recovered markedly ( $>0.5 \times 10^9$  neutrophils  $\text{l}^{-1}$  on day 4) and the patient's temperature became normal on day 8. Repeated CT scan of the chest on day 14 showed, however, a progression of the pulmonary infiltrates. Thus antifungal therapy was changed to caspofungin (first dose 70 mg on day 15, then 50 mg daily) and a CT-guided lung biopsy was performed on day 16.

In the lung biopsy, elongated yeast-like fungal structures were detected by microscopy with the calcofluor white stain (Fig. 2a). In addition, histopathology of the biopsy specimens revealed mycelial structures by Grocott–Gomori

Abbreviation: CT, computed tomography.

The GenBank/EMBL/DDBJ accession numbers for the internal transcribed spacer and  $\beta$ -tubulin sequences of the *Ophiostoma piceae* isolate are FJ230885 and FJ230886, respectively.

A neighbour-joining tree showing the relationship of the *O. piceae* isolate obtained in this study with *Sporothrix schenckii* is available with the online version of this paper.

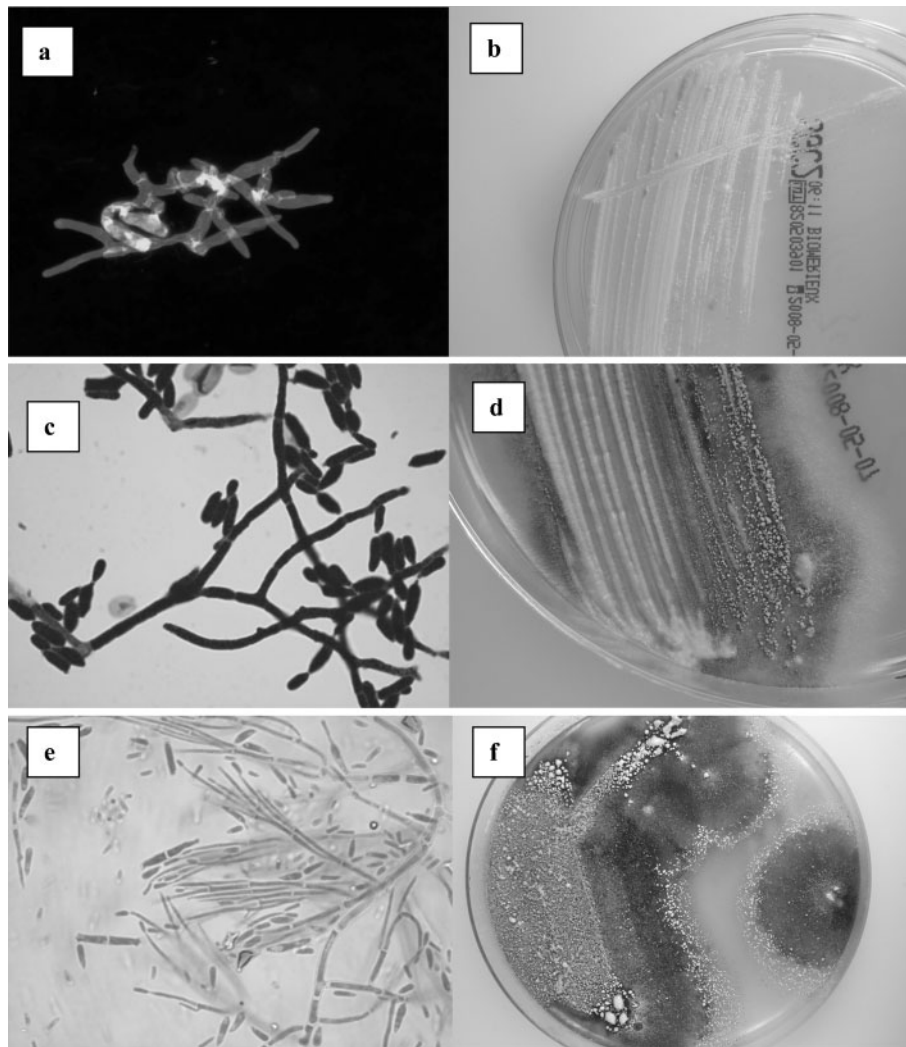


**Fig. 1.** (a) CT scan of the chest on day 2; (b) MRI scan of the brain on day 5.

staining, which could not be further identified due to autolysis of the specimen. After 48 h incubation at 30 °C, plenty of whitish colonies of approximately 1 mm diameter were cultured on Sabouroud dextrose agar (SDA, bioMérieux; Fig. 2b). Microscopy of the colonies revealed elongated cells as well as mycelial structures (Fig. 2c). The colonies developed aerial mycelial structures and darkened coloration after further incubation at room temperature (Fig. 2d) and microscopy revealed a predominance of septated mycelium (Fig. 2e). Subcultures on potato glucose agar (BD) at room temperature and 30 °C confirmed the growth characteristics observed on SDA (Fig. 2f); however, production of mycelium at 30 °C was reduced on this agar. For a more detailed investigation of temperature tolerance, the strain was point-inoculated on oatmeal agar culture plates at room temperature in duplicate, and subjected to constant temperatures of 27, 30, 33 and 36 °C in darkness, with or without pre-incubation for 2 days at room temperature. Growth expansion was measured every second day over 1 week. Consistent growth was obtained at 27 °C. Without pre-incubation, no growth was observed at 30 °C and above. With pre-incubation, colonies reached 30 mm in 7 days at 27 °C, down to 1.5 mm at 36 °C. Colonies at 27–33 °C were cottony, while those at 36 °C were smooth. The latter colonies showed low-frequency conversion of conidia into chlamyospore-like cells, and hyphae were very thin, but no yeast phase was observed. Growth on Mycosel agar (BD) at 27 °C was not inhibited by cycloheximide. Although the morphology was not really typical, infection by a fungus closely related to *Sporothrix schenckii* was initially suspected. Apart from this fungus, no other fungi or bacteria were cultured from the biopsy. Susceptibility testing of the isolate by E-test (Viva Diagnostics) on RPMI agar (72 h incubation at room temperature) revealed the following MICs: fluconazole >256 µg ml<sup>-1</sup>, itraconazole 0.125 µg ml<sup>-1</sup>, voriconazole

0.19 µg ml<sup>-1</sup>, posaconazole <0.002 µg ml<sup>-1</sup>, flucytosine 0.047 µg ml<sup>-1</sup>, caspofungin 0.25 µg ml<sup>-1</sup>, amphotericin B <0.002 µg ml<sup>-1</sup>. For final identification, sequencing of the internal transcribed spacer (ITS) regions 1 and 2, including the 5.8S gene, the rRNA operon, as well as the partial  $\beta$ -tubulin gene, was performed using primers and protocols of De Hoog *et al.* (2007). The sequences were deposited in GenBank with the accession numbers FJ230885 (ITS sequence) and FJ230886 ( $\beta$ -tubulin gene). Comparisons with previously published sequences from GenBank and phylogenetic analyses (maximum-likelihood, maximum-parsimony and Bayesian) of the data confirmed the identity of the isolate as *Ophiostoma piceae* (Fig. 3). The identification was verified at the Centraalbureau voor Schimmelcultures (CBS) and the strain was deposited in the CBS culture collection (CBS 123358).

Following the guidelines for management of sporotrichosis (Kauffman *et al.*, 2007), antifungal treatment was changed from caspofungin to itraconazole (400 mg daily per os) on day 36, resulting in a significant reduction of the pulmonary lesion but rapid progression of cerebral symptoms. Neurosurgical resection of the abscess was performed on day 46, and in the biopsy specimens fungal structures were observed by microscopy with calcofluor white stain that were morphologically equal to those seen microscopically in the lung biopsy (Fig. 2a). However, the fungus was no longer detectable by culture. A Rickham reservoir was implanted, and, using this access, liposomal amphotericin B (0.01–0.3 mg daily) was instilled into the cerebral lesion, followed by significant clinical improvement. However, treatment of lymphoma was not completed due to the severe fungal infection and 6 months after first complete remission of the lymphoma a systemic relapse with bone marrow involvement was diagnosed. The patient rejected reinduction therapy and died a few weeks later.

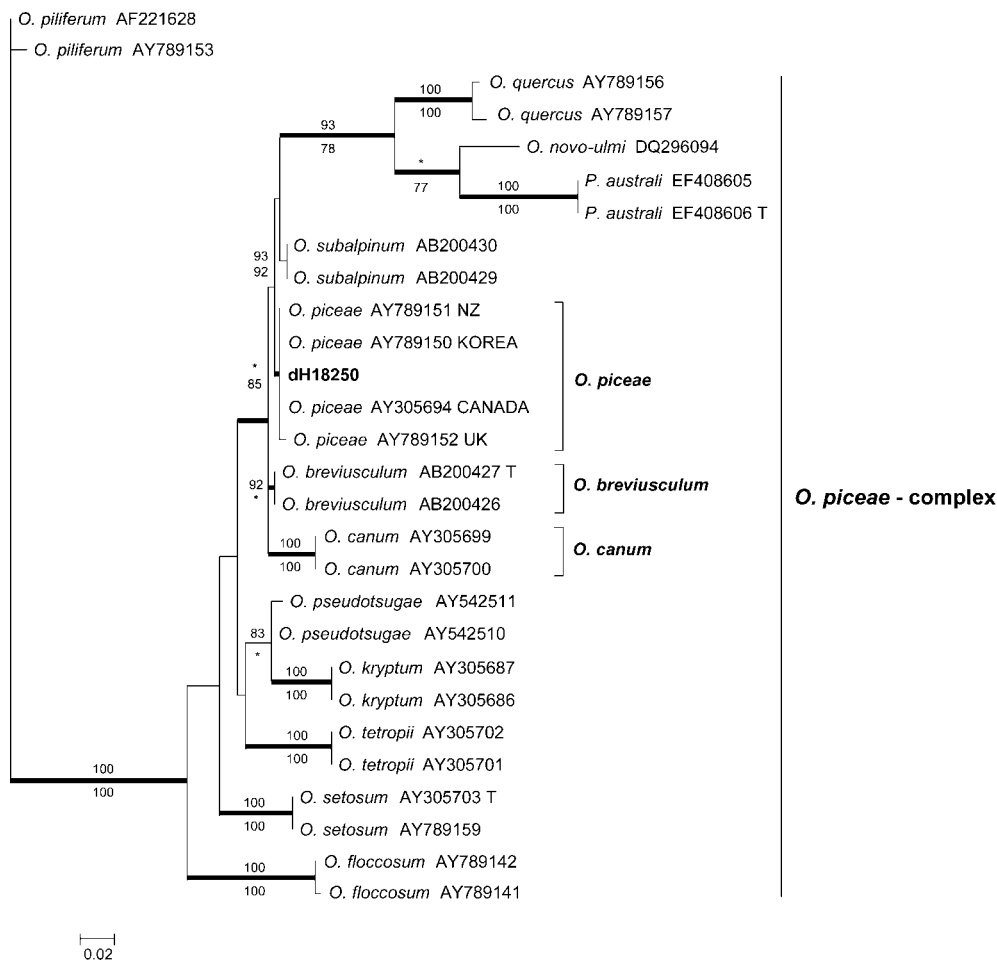


**Fig. 2.** (a) Calcofluor white stain of lung biopsy sample (magnification 600-fold). (b) Culture on SDA after 3 days incubation at 30 °C. (c) Gram stain of fungal colonies from SDA after 4 days of incubation at 30 °C (magnification 600-fold). (d) Culture on SDA after 4 days incubation at room temperature. (e) Lactophenol blue preparation from colonies grown on SDA for 4 days at room temperature. (f) Culture on potato dextrose agar after 2 weeks incubation at room temperature.

## Discussion

To our knowledge, this is the first case of invasive fungal infection caused by an *Ophiostoma* species. The genus *Ophiostoma* is the largest of the four teleomorph (sexual) genera of the Ophiostomatales (Ascomycetes). However, for several species in the genus, only anamorph (asexual) states are known. These asexually reproducing species, although phylogenetically placed in the *Ophiostoma*, are classified in one of three anamorph genera: *Sporothrix*, *Hyalorhinocladiella* or *Pesotum* (Zipfel *et al.*, 2006). The majority of the approximately 160 species of *Ophiostoma* (including the anamorph species) are wood-inhabiting saprophytes associated with bark beetle vectors. A few of the species are serious tree pathogens. One subgroup of *Ophiostoma*, the so-called *Ophiostoma stenoceras*-*S.*

*schenkii* complex (Supplementary Fig. S1 in JMM Online), produces *Sporothrix* anamorphs and contains several soil-inhabiting species, including the human pathogen *S. schenkii* (De Beer *et al.*, 2003a; De Meyer *et al.*, 2008). *O. piceae*, however, belongs to another subgroup of the genus, the *O. piceae* complex, and causes blue-stain in the sapwood of trees and logs (Harrington *et al.*, 2001). The complex also includes the causal agents of the notorious Dutch elm disease, *Ophiostoma ulmi* and *Ophiostoma novo-ulmi*, that wiped out millions of elm trees during the previous century in Eurasia and North America (Brasier, 1990). All the species in the *O. piceae* complex have hitherto been regarded as non-pathogenic to humans. *O. piceae* has a global distribution, non-specific associations with many bark beetle vectors, a wide host range and occurs commonly in areas where freshly felled



**Fig. 3.** Neighbour-joining tree obtained by maximum-likelihood (ML) analysis of the partial  $\beta$ -tubulin gene, identifying the patient isolate as *Ophiostoma piceae*. Bootstrap values for ML are indicated above, and those for maximum-parsimony below, branching points. Posterior probabilities >95%, obtained from Bayesian analyses, are indicated by bold lines.

timber is handled and stored, or on injured or stressed trees in native forests and commercial plantations (De Beer *et al.*, 2003b; Harrington *et al.*, 2001; Kirisits, 2004).

Due to the wide distribution of *O. piceae* in the environment, infection in humans may be acquired by several modes, including direct inoculation through trauma, and/or pulmonary inhalation of the airborne conidia of the *Sporothrix* anamorph. Since biopsies were not done on the skin lesions in our patient, it remains open whether these lesions represented the initial focus of infection. Due to his profession as a gardener living in a rural environment, the patient might have had an increased exposure to the fungus. Since the *Ophiostoma* isolate did grow significantly less well at 36 °C than at lower temperatures in the laboratory, the pathogenic potential of the isolate may be lower than that of more heat-tolerant species. However, invasive infections with high mortality in immunocompromised patients by other filamentous fungi that do not grow well or at all at 36 °C in the laboratory, like some species of the genera

*Chrysosporium*, *Mucor*, *Curvularia* and *Alternaria*, are known (Morrison *et al.*, 1993).

Identification of *O. piceae* in the clinical microbiology laboratory is a challenge. Occurrence of loosely aggregated hyphae (Fig. 2e) has been described for *O. piceae* (Przybyl & De Hoog, 1989) and may help to differentiate this species from *S. schenckii*. In addition, clustered denticles as seen in *S. schenckii* are missing. The *Ophiostoma* strain showed good growth at 27 °C but proved to be temperature-sensitive in showing no growth at higher temperatures if pre-incubation at room temperature was omitted. Rudimentary, smooth colonies were obtained after 1 week at 36 °C. At this temperature, conidia were still abundant, though supported by fragile hyphae, while hyaline chlamydospore-like cells were also obtained. An unambiguous yeast phase as in *S. schenckii* remained absent. Molecular identification methods, such as ribosomal gene sequencing, are necessary for accurate identification of this species.

Optimal treatment of patients with *Ophiostoma* infection is unclear, and methods for antifungal susceptibility testing as well as interpretative criteria for test results have not been validated. Due to the close relationship to *S. schenckii* and the comparably low MIC value for itraconazole, high-dose itraconazole therapy for 10 weeks (Gullberg *et al.*, 1987; McGinnis *et al.*, 2001; Van Cutsem, 1992) was chosen, resulting in improvement of the patient and partial regression of the lesions. Nevertheless, progression of the underlying disease led to the fatal outcome in the patient. Since this *Ophiostoma* infection developed under prophylactic treatment with voriconazole (given, however, in a therapeutical dosage of 400 mg daily), it may be discussed whether the first-line and long-term azole therapy was adequate. *In vitro* susceptibility testing did not reveal increased MIC values for itraconazole or voriconazole, and treatment with itraconazole showed some clinical and radiologically documented success regarding the pulmonary lesion. However, for cure of cerebral lesions caused by *Ophiostoma*, amphotericin B or an azole with good penetration into cerebrospinal fluid, like voriconazole, may be required. After intracerebral instillation of amphotericin B, the patient improved significantly. Nevertheless, susceptibility testing of isolates appears to be recommended since the sensitivity of *S. schenckii* to amphotericin B has been reported to be strain-dependent (McGinnis *et al.*, 2001). According to *in vitro* studies, echinocandins have less activity than triazoles against *S. schenckii* and other dimorphic fungi (Espinel-Ingroff, 1998) and, thus, after final identification of the isolate, therapy was changed from caspofungin to an azole. In further cases, posaconazole may also be a promising antimycotic agent since it had the lowest MIC of all azoles.

In conclusion, ubiquitous fungi from the genus *Ophiostoma* may represent a new group of human-pathogenic fungi in immunocompromised patients. This fatal case of *O. piceae* infection emphasizes the significance of invasive diagnostic measures and fungal cultures followed by molecular identification of the isolates in patients with clinical suspicion of fungal infection.

## Acknowledgements

We thank Dr Bitá Tarazooie for performing the temperature tolerance tests.

## References

Brasier, C. M. (1990). China and the origins of Dutch elm disease: an appraisal. *Plant Pathol* 39, 5–16.

- De Beer, Z. W., Harrington, T. C., Vismer, H. F., Wingfield, B. D. & Wingfield, M. J. (2003a). Phylogeny of the *Ophiostoma stenoceras-Sporothrix schenckii* complex. *Mycologia* 95, 434–441.
- De Beer, Z. W., Wingfield, B. D. & Wingfield, M. J. (2003b). The *Ophiostoma piceae* complex in the Southern Hemisphere: a phylogenetic study. *Mycol Res* 107, 469–476.
- De Hoog, G. S., Nishikaku, A. S., Fernandez Zeppenfeldt, G., Padin-Gonzalez, C., Burger, E., Badali, H., Richard-Yegres, N. & van den Ende, A. H. G. (2007). Molecular analysis and pathogenicity of the *Cladophialophora carrionii* complex, with the description of a novel species. *Stud Mycol* 58, 219–234.
- De Meyer, E. M., de Beer, Z. W., Summerbell, R. C., Moharram, A. M., de Hoog, G. S., Vismer, H. F. & Wingfield, M. J. (2008). Taxonomy and phylogeny of new wood- and soil-inhabiting *Sporothrix* species in the *Ophiostoma stenoceras-Sporothrix schenckii* complex. *Mycologia* 100, 647–661.
- Espinel-Ingroff, A. (1998). Comparison of *in vitro* activities of the new triazole SCH56592 and the echinocandins MK-0991 (L-743,872) and LY303366 against opportunistic filamentous and dimorphic fungi and yeast. *J Clin Microbiol* 36, 2950–2956.
- Gullberg, R. M., Quintanilla, A., Levin, M. L., Williams, J. & Phair, J. P. (1987). Sporotrichosis: recurrent cutaneous, articular, and central nervous system infection in a renal transplant recipient. *Rev Infect Dis* 9, 369–375.
- Harrington, T. C., McNew, D., Steimel, J., Hofstra, D. & Farrell, R. (2001). Phylogeny and taxonomy of the *Ophiostoma piceae* complex and the Dutch Elm Disease fungi. *Mycologia* 93, 111–136.
- Hoelzer, D. (2006). *Multicenter Study To Optimize Treatment of Acute Lymphoblastic Leukemia in Adults (>15 years)*. European LeukemiaNet. European Leukemia Trial Registry – Trial ALL GMALL07/2003. [http://www.leukemia-net.org/trial/download/public/ALL\\_GMALL07-03\\_ShortProtEN.pdf?id=489](http://www.leukemia-net.org/trial/download/public/ALL_GMALL07-03_ShortProtEN.pdf?id=489)
- Kauffman, C. A., Bustamante, B., Chapman, S. W. & Pappas, P. G. (2007). Clinical practice guidelines for the management of sporotrichosis: 2007 update by the Infectious Diseases Society of America. *Clin Infect Dis* 45, 1255–1265.
- Kirisits, T. (2004). Fungal associates of European bark beetles with special emphasis on the Ophiostomatoid fungi. In *Bark and Wood Boring Insects in Living Trees in Europe, a Synthesis*, pp. 181–235. Edited by F. Lieutier, K. R. Day, A. Battisti, J.-C. Grégoire & H. Evans. Dordrecht: Kluwer Academic Publishers.
- McGinnis, M. R., Nordoff, N., Li, R. K., Pasarell, L. & Warnock, D. W. (2001). *Sporothrix schenckii* sensitivity to voriconazole, itraconazole and amphotericin B. *Med Mycol* 39, 369–371.
- Morrison, V. A., Haake, R. J. & Weisdorf, D. J. (1993). The spectrum of non-Candida fungal infections following bone marrow transplantation. *Medicine (Baltimore)* 72, 78–89.
- Przybyl, K. & De Hoog, G. S. (1989). On the variability of *Ophiostoma piceae*. *Antonie Van Leeuwenhoek* 55, 177–188.
- Van Cutsem, J. (1992). *In vitro* antifungal spectrum of itraconazole and treatment of systemic mycoses with old and new antimycotic agents. *Chemotherapy* 38 (Suppl 1), 3–11.
- Zipfel, R. D., de Beer, Z. W., Jacobs, K., Wingfield, B. D. & Wingfield, M. J. (2006). Multi-gene phylogenies define *Ceratocystiopsis* and *Grosmannia* distinct from *Ophiostoma*. *Stud Mycol* 55, 75–97.