

# Invasive chromoblastomycosis and sinusitis due to *Phialophora verrucosa* in a child from northern Africa

H. Hofmann,<sup>1</sup> S.-M. Choi,<sup>1,2</sup> D. Wilsmann-Theis,<sup>1</sup> R. Horré,<sup>2,3</sup> G. S. de Hoog<sup>4</sup> and T. Bieber<sup>1</sup>

<sup>1</sup>Department of Dermatology, University of Bonn, Bonn, Germany, <sup>2</sup>Institute for Medical Microbiology and Immunology, University of Bonn, Bonn, Germany,

<sup>3</sup>Federal Institute for Drugs and Medical Devices, Bonn, Germany and <sup>4</sup>Centraalbureau voor Schimmelcultures, Utrecht, the Netherlands

## Summary

We report on a severe, verrucous facial mycosis and sinusitis in a 12-year-old Libyan girl. Her disease started with verrucous, hyperkeratotic plaques and subcutaneous violet nodules of unknown origin on her face and upper extremities. Despite topical antimycotic therapy she needed in-hospital treatment because of severely progressive tumorous cutaneous and nasal lesions. Microscopic examination of scale samples taken from the upper extremities and the face revealed brown, thick-walled fungal elements. Under the assumption of a chromoblastomycosis, an oral treatment with itraconazole and fluorocytosin was initiated, with significant improvement of the lesions. The aetiological agent was identified as *Phialophora verrucosa*.

**Key words:** chromoblastomycosis, *Phialophora verrucosa*, black yeast, rDNA Internal Transcribed Spacer, human infection.

## Introduction

Chromoblastomycosis is a chronic, cutaneous–subcutaneous mycosis with a slow evolution, which often results in disfigurement of the affected body sites.<sup>1, 2</sup> The disease is observed in tropical and subtropical regions, particularly in Japan, Southeast Asia as well as in South and Central America.<sup>3, 4</sup> Chromoblastomycosis is initiated by traumatic inoculation of fungal elements. The name of the disease stems from the fact that most of the aetiological agents present with pigmented muriform cells or Medlar bodies in tissue. Phaeohyphomycosis is a different disease entity by lacking such isodiametrically expanding structures.<sup>5</sup> Clinically, chromoblastomycosis is characterized by pseudoepitheliomatous hyperplasia with epidermal microabscesses and dermal granuloma.<sup>5, 6</sup> The initial lesion is a small pink papule at the site of inoculation that gradually enlarges. The development of superficial erythematous plaques with scaly or warty appearance probably takes several months up to several

years. As a result of acanthosis these lesions further develop into large papillomatous and verrucous plaques, often with a crusted surface. Therefore, chromoblastomycosis is also known as ‘verrucous dermatitis’. In final stages the lesions may become cauliflower-shaped in some species.<sup>5</sup>

Different climate zones each harbour their own endemic species, either *Fonsecaea pedrosoi*, *Phialophora verrucosa*, or *Cladophialophora carrionii*.<sup>1, 5–8</sup> Occasionally, chromoblastomycosis-like infections have been reported involving the closely related species *Rhinochlamydia aquaspersa*, *Exophiala spinifera* and *E. jeanselmei*.<sup>2, 9–12</sup> The agents mostly gain entry via wood splinters or cactus spines.<sup>13</sup> Rural populations of farmers and forestry workers are most likely to become infected.<sup>14–16</sup> Exposed body sites, particularly the extremities, are frequently involved, but extended lesions on the trunk have also been described.<sup>1, 4, 7, 11, 12</sup> Chromoblastomycosis causes no discomfort to the majority of patients, but may be very itching. The disease affects males more often than females, presumably because of the higher participation in agricultural work.<sup>16</sup> Mean age of involved patients is between 30 and 50 years;<sup>5, 6</sup> reports of affected children are very rare. The period between inoculation and full-blown disease may take several years.<sup>5, 6, 14</sup> With increasing long-distance tourism the disease may occasionally be observed as a vacation dermatosis.<sup>17</sup>

Correspondence: Henrike Hofmann, Department of Dermatology, University of Bonn, Sigmund-Freud-Str. 25, D-53105 Bonn, Germany.  
Tel.: +49 228 287 5557/6679. Fax: +49 228 287 4333.  
E-mail: hen75@gmx.de

Accepted for publication 11 June 2005

While most patients with phaeohyphomycosis reveal underlying immunological deficiencies, those with chromoblastomycosis are mostly in good health.<sup>5, 18</sup>

One of the relatively frequent agents, *P. verrucosa*, is presumed to be widely distributed in nature. It has been isolated from plant debris, wood piles, fence posts, tree stumps, soil and animal faeces,<sup>5, 19</sup> although the identity of most of these strains has not been verified by molecular data.

In the present study, we describe a severe case of a chromoblastomycosis by *P. verrucosa* with remarkable signs of generalized dissemination in a child from northern Africa.

### Case history

A 12-year-old Libyan girl has been suffering from extensive skin lesions on her legs, arms and face since 6 years. The girl is the 10th child of a family with altogether 12 children. Although all members of the family live close to each other under tight conditions, no other family member was affected.

The first skin lesions appeared in 1997 on the girl's nose and slowly spread over her middle-face and her extremities. A history of trauma was denied. Lesions comprised dark, sharply delimited, verrucous and hyperkeratotic plaques and subcutaneous, violet nodules on the face and extremities. The facial lesions were widely extended over her nose down to the upper lip and had a slimy coat (Fig. 1) with a foul smell. Her forehead showed one round exophytic tumorous skin lesion with a diameter of about 3 cm. Furthermore, extensive, dark pigmented areas could be seen on the palate (Fig. 2). Magnetic resonance images of her head showed widely extended infiltrates in her paranasal sinuses (Fig. 3). Despite of axillary, inguinal and submandibular lymphadenopathy the girl was in excellent health. Fever, loss of weight and sweating were denied. Only an increase of platelets, eosinophilic granulocytes and basophilic granulocytes was detected. An X-ray of the right hand implied the diagnosis of osteomyelitis of the little finger. Scaly and biopsy material were used for cultural detection and determination of the causative agent (see *Mycology*). Furthermore, skin samples from different locations (e.g. left forearm, face, right hand) were taken for histological and microbiological examination.

The patient was advised to be treated with itraconazole 400 mg day<sup>-1</sup> orally and 250 mg flucytosin day<sup>-1</sup> i.v. for 6 months in her native country, which led to remarkable improvement. She did not attend the outpatient department of the Dermatology Clinic in Bonn for a follow-up examination after the

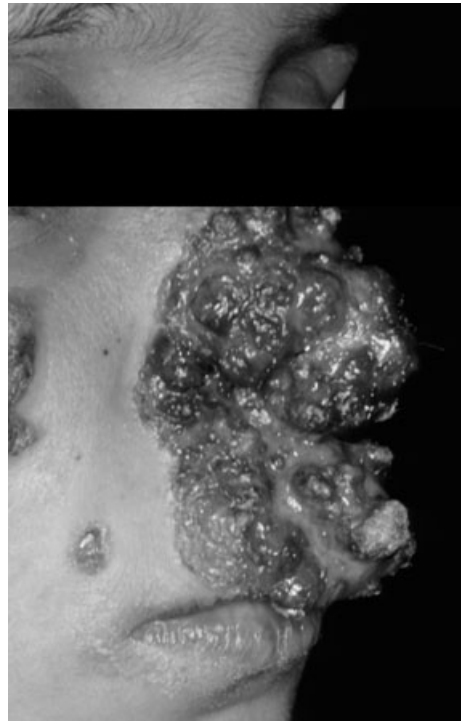


Figure 1 Facial lesions.

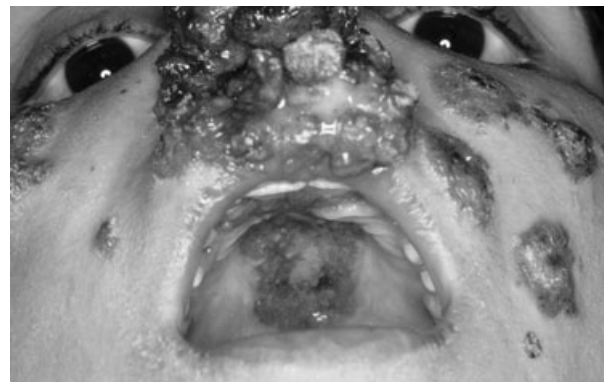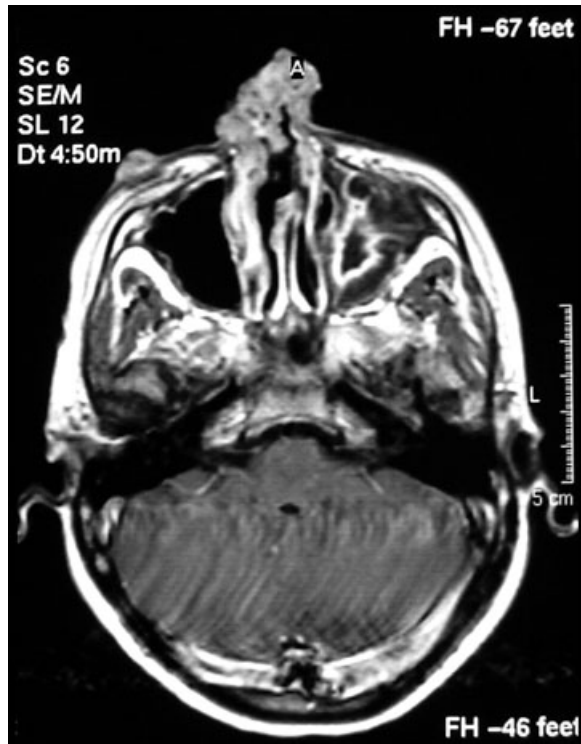


Figure 2 Palatal lesions.

6 months of therapy as planned initially. Therefore, a final outcome could not be established.

### Mycology

Tissue specimens were grown on Mycosel agar at 25 °C as well as on Sabouraud's 4% glucose agar and on Columbia 5% sheepblood agar at 37 °C. Identification with morphological and physiological criteria were



**Figure 3** Infiltrates of paranasal sinuses demonstrated with magnetic resonance imaging (MRI) scan.

performed as described in the Atlas of Clinical Fungi.<sup>20</sup> In addition, the rDNA of the Internal Transcribed Spacer (ITS) region of the isolated strain was examined with the method described by de Hoog *et al.*<sup>21–23</sup> and compared with those of reference strains of *P. verrucosa* and related species.

Colonies grew well on Mycosel culture plates, but poorly on Sabouraud's and Columbia agars. Cultures on Mycosel agar attained a diameter of 1.5–2.0 cm in about 12–14 days. The strain showed resistance against benomyl. Colonies were grey to olivaceous black, with dark greenish brown to black reverse. The mycelium was woolly to hairy, with brown, branched, septate hyphae. Flask-shaped phialides were born on undifferentiated hyphae and had distinct, dark, narrow vase-shaped collarettes. Conidia were one-celled, spherical to ellipsoidal, about  $1\text{--}3 \times 2\text{--}4 \mu\text{m}$ , accumulating at the apex of the phialide. They were subhyaline to brownish, smooth- and thin-walled. The fungus was morphologically identified as *P. verrucosa*. This diagnosis was confirmed by ITS sequence data. Nearest neighbour was isolate *P. verrucosa* CBS 225.97 at 98.4% identity. An alignment of 12 strains showed variation in 11 positions in ITS1 and eight in ITS2. Most of the

variation was unlinked and was therefore interpreted as heterozygosity. Thus, we considered the morphological identification as being confirmed. A distance tree including related fungi is presented in Fig. 4. The isolate was deposited in the culture collection of the Centraal-bureau voor Schimmelcultures as CBS 111589.

### Histopathology

Clinical manifestation was with hyperkeratotic and verrucous lesion on the left forearm. Parakeratotic crusts and acanthopapillomatous hyperplasia were present in the epithelial layer. Beneath the epidermis granulomatous infiltration of inflammatory cells and dense connective tissue were seen. Muriform fungal elements were verified by periodic acid-Schiff (PAS)-positive staining in the stratum corneum, epidermis and the adjacent connective tissues.

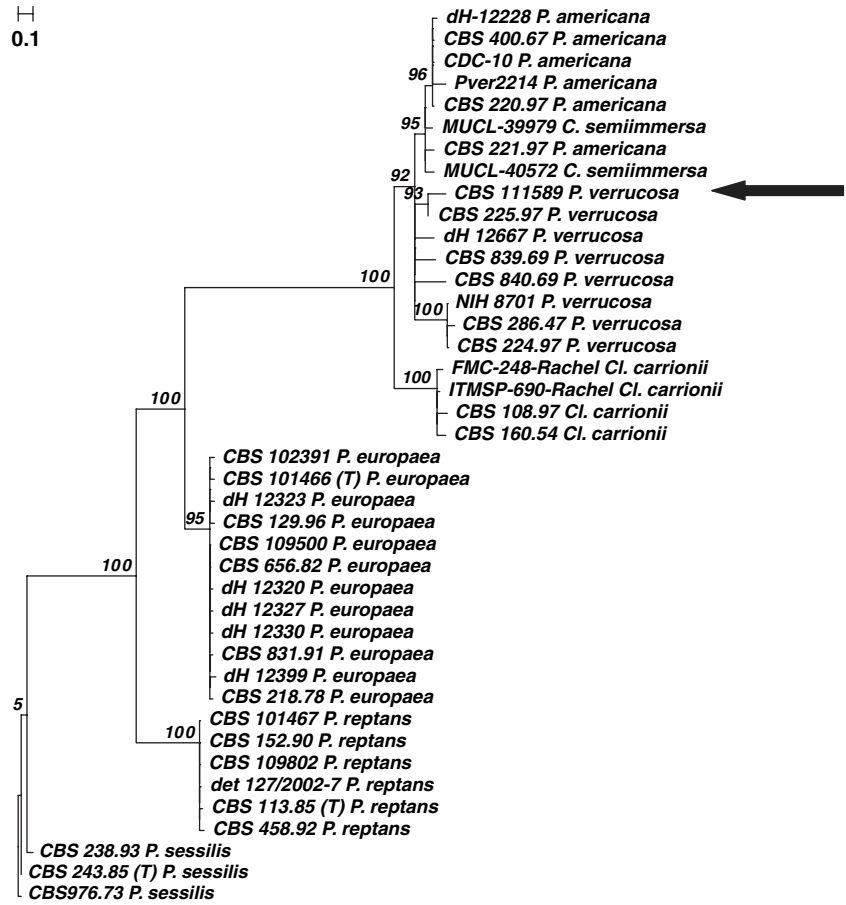
Violaceous nodules on the left thigh were examined. Upper and medium layers of the corium below regular, basically darker pigmented epithelial tissue was normal. The lower corium and the subcutis showed granulomatous infiltration with central necrosis and PAS-positive fungal elements in a nodular configuration. Granulomatous inflammation was apparent. In all scale samples round to oval, dark brown, thick-walled sclerotic bodies, so-called Medlar bodies, were visualized (Fig. 5).

### Discussion

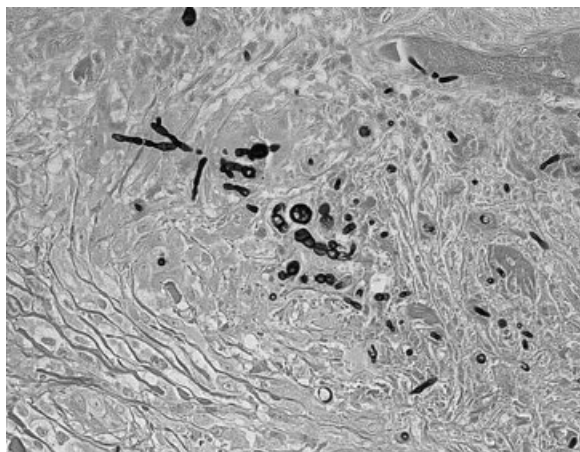
Direct examination of 10% potassium hydroxide (KOH) cleared lesion scrapings is a simple and accurate diagnostic method for the recognition of chromoblastomycosis.<sup>24</sup> Typically the pathognomonic muriform cells are seen. In some cases, dematiaceous hyphae are additionally observed. In our case the diagnosis of chromoblastomycosis could not be established microscopically but histopathologically, where the typical oval muriform elements were present.

The isolated strain had undifferentiated phialides with marked, narrow vase-shaped collarettes. It thus is morphologically similar to *P. americana*, the anamorph of *Capronia semiimmersa*,<sup>21</sup> *P. verrucosa* having wider, funnel-shaped collarettes. This distinction does not entirely correspond with the results of these species by the use of ITS sequencing. This molecular distinction proved to be robust in a tree being based on a larger number of strains (Fig. 4).

Conflicting data are present in the literature on whether the disease may disseminate to other organs. Satellite lesions can follow autoinoculation by scratch-



**Figure 4** Molecular comparison of isolates of rDNA Internal Transcribed Spacer (ITS) regions of *Phialophora verrucosa* strains in the Centraalbureau voor Schimmelcultures (CBS) culture collection.



**Figure 5** Medlar bodies in tissue.

ing or be spread lymphatically to adjacent areas. Secondary bacterial infections are common, which may lead to ulceration, lymphatic stasis and elephantiasis.<sup>5, 6</sup> Occasionally, dissemination to the brain has

been reported,<sup>5, 25</sup> but possibly misidentifications were concerned.<sup>26</sup> In immunosuppressed patients haematogenous dissemination with a poor prognosis has been described.<sup>27</sup> In those patients the typical features of chromoblastomycosis, viz. muriform cells and hyperkeratosis, may be absent. The patient described that she had initial lesions on her nose, which is an uncommon site of infection. Later pigmented areas were observed on the palate with extended infiltrates in the paranasal sinuses. The deep-seated localization of the infection, together with the concurrent lesions on the extremities, suggests systemic dissemination, as we know from *E. spinifera*, which may disseminate in healthy adolescents.<sup>21, 22</sup> In *E. spinifera*, however, chronic infection leads to multiorgan dysfunction and finally to death within a limited number of years, while our patient had remained in otherwise good health for the entire period of infection.

As spontaneous healing of chromoblastomycosis is not known, antimycotic therapy is essential in a disfiguring case like the present one. Treatment of advanced

chromoblastomycosis remains unsatisfactory despite all modern antimycotics. Many physical and pharmacological therapies have been used, such as surgical excision, cryotherapy, localized and systemic chemotherapy with amphotericin B, 5-fluorocytosine, thiabendazole, ketoconazole, fluconazole or itraconazole, all with varying results.<sup>7, 15, 28–32</sup> Curettage and cautery may cause dissemination of the infection. Therefore, such measures should be avoided.<sup>5, 6</sup> Before the azoles' era surgical excision was the most important treatment regimen, apart from sporadic physical therapy-like cryosurgery<sup>33, 34</sup> and CO<sub>2</sub>-laser therapy.<sup>35</sup> However, high rates of recurrence reduced therapeutic success. The following antimycotic treatments have been recommended: monotherapy with 5-fluorocytosine,<sup>36</sup> monotherapy with itraconazole,<sup>31, 37</sup> combination of itraconazole (400 mg die<sup>-1</sup>) and cryosurgery,<sup>15, 16</sup> combination of heating, itraconazole and amorolfine,<sup>16</sup> combination of 5-fluorocytosine (150 mg kg<sup>-1</sup> die<sup>-1</sup>) and itraconazole (200 mg die<sup>-1</sup>)<sup>38</sup> as well as monotherapy with terbinafine (500 mg die<sup>-1</sup>).<sup>39</sup> Local heat therapy, e.g. with pocket warmers are recommended in Japan.<sup>40</sup> Cryosurgery with liquid nitrogen attained good results used on localized lesions.<sup>34</sup> Systemic amphotericin B and fluconazole are not considerable in the treatment of chromoblastomycosis<sup>6, 41</sup> because of insufficient therapeutic success. Combination of different antimycotics or combination of antimycotical agents and physical treatment or surgery seem to be more effective than monotherapy.<sup>32</sup> The best results were obtained in a Mexican study using cryosurgery for small lesions, with itraconazole for large ones, and in some cases the combination of both treatments.<sup>15, 16</sup> The systemic therapy with itraconazole is indicated as the best choice<sup>29, 42, 43</sup> and it produces dramatic improvement after a few months, but a complete cure of severe cases is rarely reached. The few studies on the combination of itraconazole and 5-fluorocytosine seem to be promising.<sup>38</sup> Overall the results of the various treatments have been summarized as follows: 31% were cured, 57% improved and 12% failed.<sup>15, 16</sup> *In vitro* data show that voriconazole may be particularly promising.<sup>43</sup> In the present case, a remarkable improvement was achieved by monotherapeutic treatment with itraconazole.

Given the chronic nature of chromoblastomycosis and the frequent recurrence after treatment, there should be considerable follow up with treatment for at least two periods after clinical healing and until two consecutive negative microscopic and cultural examinations are obtained.<sup>32</sup> Therapy recommendations for chromoblastomycosis and other infections by dematiaceous fungi may vary significantly with indi-

vidual cases, and clinical controlled studies are still lacking.

## References

- 1 Milam CP, Fenske NA. Chromoblastomycosis. *Dermatol Clin* 1989; **7**: 219–25.
- 2 Bayles MAH. Chapter 45. Chromoblastomycosis. In: Hay RJ (ed.), *Balliere's Clinical Tropical Medicine and Communicable Diseases*. Philadelphia, USA: Balliere-Tindale, 1989: 69.
- 3 Arenas R. Chromoblastomycosis. In: Jacobs PH, Nall L (eds), *Antifungal Drug Therapy: A Complete Guide for the Practitioner*. New York, USA: Marcel-Dekker, 1990: 43–51.
- 4 Kwon-Chung KJ, Bennett JE (eds). Chromoblastomycosis. In: *Medical Mycology*. Philadelphia, USA: Lea and Febiger, 1992: 337–55.
- 5 McGinnis MR. Chromoblastomycosis and phaeohyphomycosis: new concepts, diagnosis, and mycology. *J Am Acad Dermatol* 1983; **8**: 1–16.
- 6 Vollum DI. Chromomycosis: a review. *Br J Dermatol* 1977; **96**: 454–8.
- 7 Fader RC, McGinnis MR. Infections caused by dematiaceous fungi: chromoblastomycosis and phaeohyphomycosis. *Infect Dis Clin North Am* 1988; **2**: 925–38.
- 8 Ajello L. Hyalohyphomycosis and phaeohyphomycosis: two global disease entities of public health importance. *Eur J Epidemiol* 1986; **2**: 243–51.
- 9 South DA, Brass C, Stevens DA. Chromoblastomycosis. Treatment with ketoconazole. *Arch Dermatol* 1981; **117**: 311–2.
- 10 Naka W, Harada T, Nishikawa T, Fukushiro R. A case of chromoblastosis: with special reference to the mycology of the isolated *Exophiala jeanselmei*. *Mykosen* 1986; **29**: 445–52.
- 11 Barba-Gomez JF, Mayorga J, McGinnis MR, Gonzalez-Mendoza A. Chromoblastomycosis caused by *Exophiala spinifera*. *J Am Acad Dermatol* 1992; **26**: 367–70.
- 12 Padhye AA, Hampton AA, Hampton MT, Hutton NW, Prevost-Smith E, Davis MS. Chromoblastomycosis caused by *Exophiala spinifera*. *Clin Infect Dis* 1996; **22**: 331–5.
- 13 Zeppenfeldt G, Richard-Yegres N, Yegres F. *Cladosporium carionii*: hongo dimorfo en cactaceas de la zona endemica para la cromomycosis en Venezuela. *Rev Iberoam Micol* 1994; **11**: 61–3.
- 14 Minotto R, Bernade CD, Mallmann LF, Edelweiss MI, Scroferneker ML. Chromoblastomycosis: a review of 100 cases in the state of Rio Grande do Sul, Brazil. *J Am Acad Dermatol* 2001; **44**: 585–92.
- 15 Bonifaz A, Martinez-Soto E, Carrasco-Gerard E, Peniche J. Treatment of chromoblastomycosis with itraconazole, cryosurgery and a combination of both. *Int J Dermatol* 1997; **36**: 542–7.

- 16 Bonifaz A, Carrasco-Gerard E, Saul A. Chromoblastomycosis: clinical and mycologic experience of 51 cases. *Mycoses* 2001; **44**: 1–7.
- 17 Mayer P, Gründer K, Quadripur S, Köhn F-M, Schill WB, de Hoog GS. Diagnostik, Klinik und Therapien der frühen Chromoblastomykose an einem Fallbeispiel. *Hautarzt* 1996; **47**: 693–701.
- 18 Matsumoto T, Matsuda T. Chromoblastomycosis and phaeohyphomycosis. *Semin Dermatol* 1985; **4**: 240–51.
- 19 Summerbell RC, Krajden S, Kane J. Potted plants in hospitals as reservoirs of pathogenic fungi. *Mycopathologia* 1989; **106**: 13–22.
- 20 de Hoog GS, Guarro J, Gené J, Figueras MJ. *Atlas of Clinical Fungi*, 2nd edn. Utrecht, the Netherlands/Reus, Spain: Centraalbureau voor Schimmelcultures/Universitat Rovira i Virgili, 2000: 1124.
- 21 de Hoog GS, Poonwan N, Gerrits van den Ende AHG. Taxonomy of *Exophiala spinifera* and its relationship to *E. jeanselmei*. *Stud Mycol* 1999; **43**: 133–42.
- 22 de Hoog GS, Weenink XO, Gerrits van den Ende AHG. Taxonomy of the *Phialophora verrucosa* complex with the description of two new species. *Stud Mycol* 1999; **43**: 107–22.
- 23 de Hoog GS, Mayer P, Haase G, Horré R, Horrevorts AM. A new species of *Phialophora* from human skin. *Mycoses* 2000; **43**: 409–16.
- 24 Zaias N, Rebell G. A simple and accurate diagnostic method in chromoblastomycosis. *Arch Dermatol* 1973; **108**: 545–6.
- 25 Shimoaka S, Waga S. Case report: Cerebral chromoblastomycosis complicated by meningitis and multiple fungal aneurysms after resection of a granuloma. *J Neurosurg* 1983; **59**: 158–61.
- 26 Horré R, de Hoog GS. Primary cerebral infections by melanized fungi: a review. *Stud Mycol* 1999; **43**: 176–93.
- 27 Lundstrom TS, Fairfax MR, Dugan MC *et al.* *Phialophora verrucosa* infection in a BMT patient. *Bone Marrow Transplant* 1997; **20**: 789–91.
- 28 Lavallo P. Chromoblastomycosis. In: Canizares O, Harmann RRM (eds), *Clinical tropical Dermatology*, 2nd edn. Boston, USA: Blackwell Scientific publications, 1992: 73–80.
- 29 Queiroz-Telles F, Purim KS, Fillus JN *et al.* Itraconazole in the treatment of chromoblastomycosis due to *Fonsecaea pedrosoi*. *Int J Dermatol* 1992; **31**: 805–12.
- 30 Smith CH, Barker JNWN, Hay RJ. A case of chromoblastomycosis responding to treatment with itraconazole. *Br J Dermatol* 1993; **128**: 436–9.
- 31 Yu R. Successful treatment of chromoblastomycosis with itraconazole. *Mycoses* 1995; **38**: 79–83.
- 32 Tintelnot K. Infektionen durch Schwärzepilze. *Mycoses* 1997; **40**(Suppl. 1): 91–6.
- 33 Lubritz PR, Spence JE. Chromoblastomycosis: cure by cryosurgery. *Int J Dermatol* 1978; **17**: 830–2.
- 34 Pimentel ER, Castro LG, Cuce LC, Sampaio SA. Treatment of chromomycosis by cryosurgery with liquid nitrogen: a report on eleven cases. *J Dermatol Surg Oncol* 1989; **15**: 72–7.
- 35 Kuttner BJ, Siegle RJ. Treatment of chromomycosis with a CO<sub>2</sub>-laser. *J Dermatol Surg Oncol* 1986; **12**: 965–8.
- 36 Kombila M, Gomez de Diaz M, Richard-Lenoble D *et al.* La chromoblastomycose au Babon Étude de 64 cas. *Cah Sante* 1995; **5**: 235–44.
- 37 Duggan JM, Wolf MD, Kauffman CA. *Phialophora verrucosa* infection in an AIDS patient. *Mycoses* 1995; **38**: 215–8.
- 38 Pradinaud R, Bolzinger T. Treatment of chromoblastomycosis. *J Am Acad Dermatol* 1991; **25**: 869–70.
- 39 Esterre P, Inzan CK, Ramarcel ER *et al.* Treatment of chromomycosis with terbinafine: preliminary results of an open pilot study. *Br J Dermatol* 1996; **134**(Suppl. 46): 33–6.
- 40 Kinbara T, Fukushiro R, Eryu Y. Chromomycosis – report of two cases successfully treated with local heat therapy. *Mykosen* 1982; **25**: 689–94.
- 41 Diaz M, Negroni R, Montero-Gei F *et al.* A Pan-American 5-year-study of fluconazole therapy for deep mycoses in the immunocompetent host. *Clin Infect Dis* 1992; **14**(Suppl. 1): 68–76.
- 42 Restrepo A, Gonzales A, Gomes I, Arango M, de Bedout C. Treatment of chromoblastomycosis with itraconazole. *Ann N Y Acad Sci* 1988; **544**: 504–16.
- 43 Graybill JR. Future directions of antifungal chemotherapy. *Clin Infect Dis* 1992; **14**(Suppl. 1): S170–80.