

Postmortem isolation of *Pseudotaeniolina globosa* from a patient with aortic aneurysm

Post-mortem-Isolierung von *Pseudotaeniolina globosa* von einem Patienten mit Aortenaneurysma

O. Kurzai,¹ P. Keith,² S. de Hoog,³ M. Abele-Horn¹ and M. Frosch¹

Departments of ¹Hygiene and Microbiology and ²Cardiothoracic Surgery of the University of Würzburg, Würzburg, Germany and ³Centraalbureau voor Schimmelcultures, Utrecht, The Netherlands

Summary

We describe the isolation of the melanized meristematic fungus *Pseudotaeniolina globosa* from the aortic wall of a patient who died while undergoing surgery for aortic aneurysm and aortic valve regurgitation as a result of dilated cardiomyopathy. Meristematic fungi related to *P. globosa* have until now been considered as environmental saprobes found predominantly in ecological niches with low water activity. The isolate was identified by phenotypic analyses and by sequencing of the rDNA internal-transcribed spacer domain. The clinical significance of this isolation remains unclear but isolation of meristematic fungi from clinical specimen should be thoroughly evaluated in terms of their significance in future.

Zusammenfassung

In diesem Fallbericht beschreiben wir die Isolierung der melanisierten meristematischen Spezies *Pseudotaeniolina globosa* aus der Aortenwand eines Patienten, der unter der Operation eines Aortenaneurysmas in Kombination mit Aortenklappeninsuffizienz und dilatativer Kardiomyopathie verstarb. Meristematische Verwandte von *P. globosa* wurden bisher als saprophytäre Umweltpilze angesehen, die vorwiegend in ökologischen Nischen mit geringer Wasseraktivität zu finden sind. Das beschriebene Isolat wurde durch phänotypische Charakteristika und die Sequenzierung der rDNA intern transkribierten Spacerregionen identifiziert. Die klinische Relevanz dieser Isolierung bleibt unklar, aber die Isolierung von meristematischen Pilzen aus klinischen Materialien sollte in Zukunft genau im Hinblick auf ihre Bedeutung evaluiert werden.

Key words: *Pseudotaeniolina globosa*, aortic aneurysm, meristematic fungi, melanized fungi.

Schlüsselwörter: *Pseudotaeniolina globosa*, Aortenaneurysma, meristematische Pilze, melanisierte Pilze.

Introduction

Meristematic black fungi are commonly encountered as environmental saprobes, growing in habitats with low

water activity such as rock surface, on lichens or conifer needles.¹ Some species are adapted to extremely adverse environments, like *Trimmatostroma salinum* Zalar *et al.*, that has been isolated from hypersaline waters.^{2,3} To date, only few meristematic black fungi have been characterized using modern techniques. Application of sequencing of the ribosomal operon has led to the description of new phylogenetic species, mainly classified in the genera *Trimmatostroma* or *Coniosporium*.^{1,4} Until now, meristematic fungi have not been associated with animal or human disease (F. de Leo, C. Urzì and

Correspondence: Dr Oliver Kurzai, Institute of Hygiene and Microbiology, University of Würzburg, Josef-Schneider-Str. 2, D-97080 Würzburg, Germany. Tel.: +49 (0)931 20146905. Fax: +49 (0)931 20146445. E-mail: okurzai@hygiene.uni-wuerzburg.de

Accepted for publication 18 November 2002

G.S. de Hoog, personal communication). Here we describe the first isolation of *Pseudotaeniolina globosa* (F. de Leo, C. Urzi and G.S. de Hoog, personal communication) from a fatal case of aortic aneurysm in combination with aortic valve regurgitation and dilated cardiomyopathy. A causal relationship between the course of disease and the presence of this fungus remains unclear. The isolate described constitutes only the third strain of *P. globosa* known to date.

Case report

A 57-year-old male patient was admitted to the cardiothoracic department for elective surgery of aortic valve regurgitation and dilation of the proximal aorta. He had a history of hepatitis A and B infection (HbS antigen negative). The patient had suffered from exertional dyspnoea for some weeks, absolute arrhythmia with atrial flutter was present. Medication at hospital admission included digitalis (0.1 mg q.d.), carvedilol (12.5 mg b.i.d.) and acetyl-salicylic acid (100 mg q.d.).

Transthoracic and transoesophageal echocardiography and catheterization of the left and right heart showed a severely reduced left-ventricular function with a cardiac index of $1.6 \text{ l min}^{-1} \text{ sqm}^{-1}$ BS and an EF of 20%. Left-ventricular end-diastolic pressure and PAP were elevated at 25 mmHg respectively. Concomitant coronary heart disease could be ruled out by coronary angiography. The maximum diameter of the ascending aorta was measured at 55 mm. Thoracic X-ray showed an enlarged heart consistent with cardiomyopathy and some kinking of the aorta, but no signs of volume overload. Electrocardiogram revealed absolute arrhythmia at a rate of 75–90 bpm, left-ventricular hypertrophy with a positive Sokolow–Lyon index and an ascending ST-fragment.

Surgical intervention was primarily directed towards reconstruction of the aortic valve and supracoronary prosthetic replacement of the aorta ascendens with a 30 mm Dacron tube-graft. As the intraoperative results of this intervention were not satisfactory, prosthetic replacement of the valve with a 25 mm bi-leaflet device was performed. During the procedure, the thin and fragile aortic wall made completion of the anastomoses difficult. Owing to the frequent left-ventricular pump failure, weaning from extra-corporeal circulation (ECC) failed and intra-aortic balloon counter-pulsation (IABP) together with extra-corporeal membrane oxygenation (ECMO) were initiated. After several hours of ECC time additional bleeding complications occurred and acidosis became irreversible. The patient died in tabula under maximum therapy with catecholamines and mechan-

ical circulatory support after 9 h of surgery with a total of 7 h 40 min of ECC because of global cardiac failure with low-output syndrome.

Routinely taken specimen of the proximal aortic wall gave no evidence for cystic media necrosis of the aorta (Gsell–Erdheim syndrome). However, the aortic wall showed lymphocytic vasculitis of the vasa vasorum, arterosclerosis and mesaortitis with profound structural disturbances of the aortic wall. Microbiology cultures were taken from the intraoperative aortic wall specimen. Microscopic examination of the specimen in a Grocott–Gomori silver stain revealed yeast-like structures (Fig. 1). Upon prolonged incubation for 8 days at 26 °C on Sabouraud glucose agar (SDA), three pigmented colonies became visible. Subcultures were grown on potato glucose agar (PDA) and oatmeal agar (OA) at 26 °C. Older colonies were compact with macroscopically visible mycelial structures and raised considerably from the agar (Fig. 2). Colony surface appeared irregularly folded (Fig. 2). No growth of the fungus could be observed at 37 and 40 °C on SDA, PDA and OA. Microscopy of a direct preparation and later examination of a slide culture revealed dark, melanized, septate hyphae and abundant spherical budding cells with a diameter of approximately 10 µm, that were also strongly pigmented (Fig. 3). Roughly half of the budding cells were smooth-walled, whereas the other half showed a structured surface (Fig. 3). For species identification, DNA was isolated from a 28-day-old culture using the protocol described by De Hoog *et al.*⁵ Internal transcribed spacer regions were amplified from genomic DNA using primers ITS1 and ITS4.^{6,7} Double-strand sequencing was achieved using the same primers. The

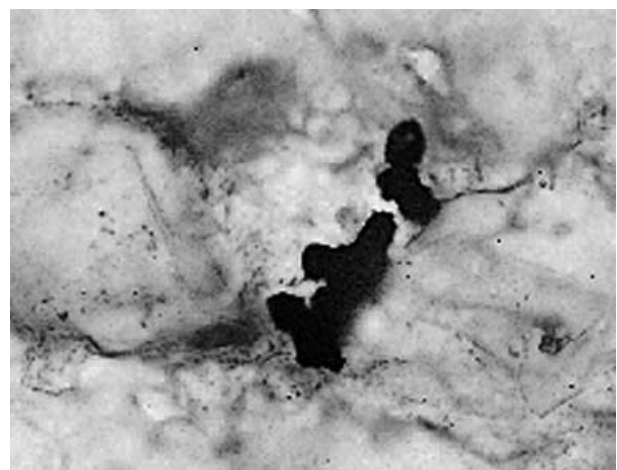


Figure 1 Microscopy of yeast-like structures in a Grocott–Gomori-stained specimen from the aortic wall (100× oil immersion) ×300.



Figure 2 Colony of *Pseudotaeniolina globosa* on oatmeal agar, 21 days. Colonies raise considerably from the agar surface. On top of the solid colony mycelial growth develops $\times 4$.

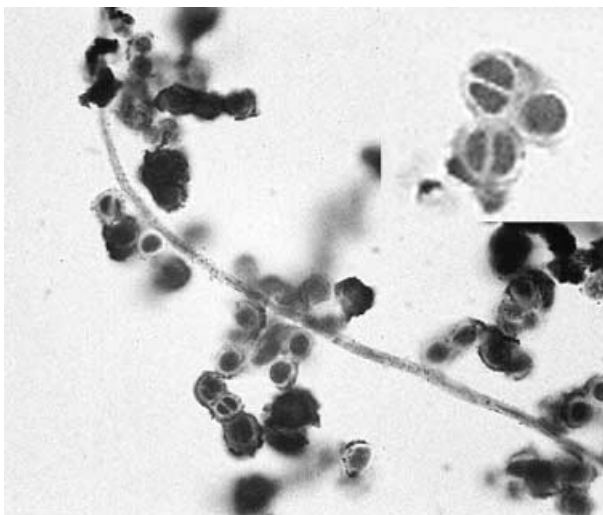


Figure 3 Microscopy of *Pseudotaeniolina globosa* on oatmeal agar, 21 days. Spherical, pigmented single cells with rough surface structure and with or without septum are predominant. A hyphal structure can be seen $\times 200$. Inlet: higher magnification illustrates the septation $\times 500$.

resulting sequence was 99% homologous to GenBank deposit AJ244268,⁸ which is now found to belong to the newly described species *P. globosa*.⁴ The strain was deposited in the culture collection of the Centraalbureau voor Schimmelcultures, Utrecht, the Netherlands, as CBS 110352. To date, only two other isolates of this species are known, both from environmental ecological niches with low water activity.⁴

Discussion

Infections caused by fungi that have previously not been known as etiologic agents of disease become more and more frequent. Here we describe the isolation of a black meristematic fungus, *P. globosa*, from a patient with aortic aneurysm in combination with dilated cardiomyopathy and aortic valve regurgitation. No antibiotic or antifungal treatment was administered in the case reported herewith because of a lack of clinical evidence for infection. However, fungal infections can progress slowly and need not necessarily be accompanied by severe inflammation. Histology of *P. globosa* infection revealed an atypical pattern of inflammation of the aortic wall. The unusually fragile structure of the aortic wall was noticed during surgery. However, the patient did not display any clinical signs suggestive of an ongoing inflammatory process. In culture, the isolate was unable to grow at 37 or 40 °C, but this does not exclude the possibility of causing invasive infections, including even brain abscesses.⁹

Melanized meristematic growth can be viewed as an adaptation to enhance survival in habitats with low water activity, for example, in rock, superficially on inert materials such as stone, painted wood, metallic instruments or leathery plant leaves, or in salty waters. Little is known about the clinical significance of this group of fungi and the potential role of this mode of adaptation for pathogenicity compared with other adaptation strategies.¹⁰ This is probably partly due to the fact that such fungi grow very slowly and have insufficient morphological characteristics to allow recognition in the routine laboratory. The only species that have been reported from medical settings are *Sarcinomyces phaeomuriformis* Matsumoto *et al.* and *Botryomyces caespitosus* de Hoog and Rubio.^{5,11,12} The former is now recognized to be an *Exophiala* species¹¹ and thus belongs to the Ascomycete, order Chaetothyriales, while *Botryomyces* is an *Alternaria* synonym of the Pleosporales.¹² *Pseudotaeniolina* and similar epiphytic fungi, however, are of dothidealean affinity,⁴ being sister species of the opportunistic black yeast *Aureobasidium pullulans* (de Bary) Arn. The latter is a ubiquitous surface-colonizing fungus whose opportunism is likely to be associated with traumatic introduction of insufficiently sterilized medical devices. The pathogenic potential of *P. globosa* remains unclear, but a behaviour similar to that of *A. pullulans* may be expected. *Aureobasidium pullulans* is equally able to convert to a meristematic, stress-tolerant ecotype, for example, under conditions of nitrogen depletion.

Meristematic conversion as a potential virulence factor deserves further attention.

Acknowledgements

We are grateful to Conni Heeg, Birgit Hofmann and Monika Pahnke for their diagnostic mycology expertise.

References

- 1 Zalar P, de Hoog GS, Gunde-Cimerman N. *Trimmatostroma salinum*, a new species from hypersaline water. *Stud Mycol* 1999; **43**: 61–7.
- 2 Butin H, Pehl L, de Hoog GS, Wollenzien U. *Trimmatostroma abietis* sp. nov. (hyphomycetes) and related species. *Antonie van Leeuwenhoek* 1996; **69**: 203–9.
- 3 Gunde-Cimerman N, Zalar P, de Hoog S, Plemenitas A. Hypersaline waters in salterns – natural ecological niches for halophilic black yeasts. *FEMS Microbiol Ecol* 2000; **32**: 235–40.
- 4 Sterflinger K, de Baere R, de Hoog GS, de Wachter R, Krumbein WE, Haase G. *Coniosporium perforans* and *C. apollinis*, two rock-inhabiting fungi isolated from marble in the Sanctuary of Delos (Cyclades, Greece). *Antonie van Leeuwenhoek* 1997; **72**: 349–63.
- 5 de Hoog GS, Guarro J, Gené J, Figueras MJ. *Atlas of Clinical Fungi*, 2nd edn. Utrecht: Centraalbureau voor Schimmelf-cultures/Reus: Universitat Rovira i Virgili, 2002: 1126.
- 6 White TJ, Burns TD, Lee SB, Taylor JW. Amplification and direct sequencing of fungal ribosomal RNA genes for phylogenetics. In: Innis MA, Gelfand DH, Sninsky JJ White TJ (eds), *PCR Protocols*. San Diego: Academic Press, 1990: 315–22.
- 7 Kurzai O, Korting H-C, Harmsen D *et al.* Molecular and phenotypic identification of the yeast pathogen *Candida dubliniensis*. *J Mol Med* 2000; **78**: 521–9.
- 8 de Hoog GS, Zalar P, Urzì C, De Leo F, Yurlova NA, Sterflinger K. Relationships of dothideaceous black yeasts and meristematic fungi based on 5.8S and ITS2 rDNA sequence comparison. *Stud Mycol* 1999; **43**: 31–37.
- 9 Seeliger HPR. Infections of man by opportunistic molds – their identification and nomenclature of their diseases. *Mykosen* 1983; **26**: 587–98.
- 10 Kurzai O, El Barkani A, Mühlischlegel FA. Adaptation of fungi to alterations of the environmental pH. In: Calderone R, Cihlar R (eds), *Fungal Pathogenesis – Principles and Clinical Applications*. New York: Marcel Dekker Inc., 2001: 139–60.
- 11 Matos T, Haase G, de Hoog GS. Ecology, molecular variation and taxonomy of oligotrophic and neurotropic members of the black yeast genus *Exophiala*. *Antonie van Leeuwenhoek* 2002; (in press).
- 12 de Hoog GS, Horré R. Molecular taxonomy of the *Alternaria* and *Ulocladium* species from humans and their identification in the routine laboratory. *Mycoses* 2002; **45**: 259–76.